

## Determination of Co-infection in Diseased Seven khramulya (*Capoeta capoeta*)

Tülay AKAYLI<sup>1</sup> , Çiğdem ÜRKÜ<sup>2</sup> , Erol Rüştü BOZKURT<sup>3</sup> 

<sup>1,2</sup>Department of Fish Disease, Faculty of Aquatic Sciences, University of Istanbul, Laleli- Istanbul, <sup>3</sup>Istanbul Education and Research Hospital, Department Pathology, Samatya-Istanbul,Turkey

<sup>1</sup><https://orcid.org/0000-0003-2375-2224>, <sup>2</sup><https://orcid.org/0000-0003-0381-9321>, <sup>3</sup><https://orcid.org/0000-0002-1349-2206>

✉: curku@istanbul.edu.tr

### ABSTRACT

This study was conducted identify the cause of mortality in diseased Seven khramulya (*Capoeta capoeta*) and to determine the damage to the fish tissue caused by the agents identified. While hemorrhage on the fins and abdominal region of diseased fish, necrosis in gills, darkening color and loss of scales were externally determined, the presence of bloody and smelling liquid in the abdominal cavity, necrosis of visceral organs, splenomegaly, hyperemia and hemorrhage in the visceral organs were internally observed. As a result of the parasitological examination, *Gyrodactylus* sp. were found on the gills of the diseased fish, and *Trichodina* sp. were found on their skin. Bacteriologically, isolated bacteria were identified as *Aeromonas hydrophila*, *Vibrio fluvialis*, *Staphylococcus warneri* and *S. capitis*. Histopathologically, thickening of epicardium in heart tissue, myopathy, periglomerular and tubular edema melanomacrophage and hemosiderin foci, the infiltration of inflammatory cells in the kidney, hyperemia, infiltration of inflammatory cells in the liver were observed. *A. hydrophila*, *V. fluvialis*, *S. warneri*, and *S. capitis* were first isolated and identified as disease agents from the co-infection in diseased Seven khramulya, and furthermore, pathological changes in tissues caused by these pathogenic bacteria were investigated in detail.

### Research Article

#### Article History

Received : 25.03.2019

Accepted : 09.05.2019

#### Keywords

Seven khramulya  
*A. hydrophila*  
*V. fluvialis*  
*Staphylococcus* spp.  
Infection

## Hasta Siraz Balıklarında (*Capoeta capoeta*) Görülen Ko-Enfeksiyonun Tanımlanması

### ÖZET

Bu çalışma, hasta siraz balıklarında (*Capoeta capoeta*) görülen ölümlerin nedenini belirlemek ve tespit edilen etkenlerin balık dokusunda meydana getirdiği hasarı tespit etmek amacıyla yürütülmüştür. Dış bakıda balıkların yüzgeçlerinde ve karın bölgesinde hemoraji, yanı sıra solungaçlarda nekroz, renkte koyulaşma ve pullarda dökülme tespit edilirken, içbakiya ise abdominal boşlukta kanlı ve kokulu bir sıvının olduğu ayrıca iç organlarda nekroz, dalakta büyüme ve iç organlarda hiperemi ve hemoraji tespit edilmiştir. Parazitolojik muayene sonucunda, incelenen hasta balıkların solungaçlarında *Gyrodactylus* sp. derisinde ise *Trichodina* sp. parazitlerine rastlanılmıştır. Bakteriyolojik olarak izole edilen bakteriler *Aeromonas hydrophila*, *Vibrio fluvialis*, *Staphylococcus warneri* ve *S. capitis* olarak tanımlanmıştır. Histopatolojik olarak, epikardiyum da kalınlaşma, miyopati, böbrek dokusunda periglomerular ve tübüler ödem, melanomakrofaj ve hemosiderin odakları yanı sıra inflamasyon hücrelerinin infiltrasyonu, karaciğerde hiperemi, infiltrasyon hücrelerinin infiltrasyonu gözlenmiştir. Bu çalışma ile hasta siraz balıklarının karma enfeksiyonundan ilk kez hastalık etkeni olarak *A. hydrophila*, *V. fluvialis*, *S. warneri* ve *S. capitis* izole ve tanımlanmıştır. Bu patojen bakterilerin dokularda meydana getirdiği patolojik değişiklikler detaylı bir şekilde araştırılmıştır.

### Araştırma Makalesi

#### Makale Tarihi

Geliş Tarihi : 25.03.2019

Kabul Tarihi : 09.05.2019

#### Anahtar Kelimeler

Siraz  
*A. hydrophila*  
*V. fluvialis*  
*Staphylococcus* spp.  
Enfeksiyon

## INTRODUCTION

The Cyprinidae family constitutes the most important family among the fish species distributed over the world (Blanc et al., 1971; Howes, 1991). The genus *Capoeta*, a member of this family, is distributed from West Asia to Central Asia, and the fish species in this genus live in fast or slow flowing lakes and rivers (Geldiay and Balik, 1996). It was reported that this genus has five species and 7 subspecies in fresh waters of Turkey (Geldiay and Balik, 1996; Demirsoy, 1997). It was also reported that the most important species that are cultured among these species were common carps (Pullin, 1986).

Seven khramulya (*Capoeta capoeta*) is a fish species with economic importance, which is consumed as food by local people in the Southeastern Anatolia Region (Geldiay and Balik, 1996; Şen and Canpolat, 2011). It was reported that the total fishing of Seven khramulya species in Turkey was 695 tons in 2015 and reached 708 tons in 2016 (TUIK, 2016). However, according to the data for 2016, it is observed that it decreased by 1.6% compared to 2015. Therefore, it was indicated that studies should be conducted on the farming of this fish (Demir, 2017).

It is remarkable that studies conducted on Seven khramulya so far have focused on different areas including the reproductive biology of this species, accumulation of heavy metal, nutrition regime and processing technology (Yılmaz et al., 2003; Yazıcıoğlu and Yılmaz, 2011; Gündüz et al., 2018). Nevertheless, the parasites causing disease in Seven khramulya were studied in detail in previous studies, and it was reported that parasites such as *Lernaea cyprinacea* (Koyun and Atıcı, 2017), *Clinostomum complanatum* (Malek and Mobedi, 2001), *Ichthyophthirius multifiliis* (Raissy et al., 2010), *Rhabdochona denudata* (Raissy and Ansari 2012) and *Ligula intestinalis* (Keskin and Erk'akan, 1987) were detected in *Capoeta capoeta*. Despite the reports indicating that bacterial pathogens such as *A. hydrophila*, *A. sobria*, *V. fluvialis*, *A. salmonicida*, *Flavobacterium* sp. cause disease in common carps in previous studies (Guz and Kozinska, 2004; Monette et al., 2006; Adanır and Turutoğlu, 2007), there is no study on the bacterial diseases of this fish, which is considered to be cultured and is a Cyprinid species.

This study was conducted to identify the agents causing mortality in Seven khramulya through parasitological and bacteriological methods and to determine the histopathological damage to tissues caused by the agents identified.

## MATERIAL and METHODS

### Fish Samples

Diseased Seven khramulya (150-200 g), which is found in freshwater in the Euphrates Region and where

deaths are observed, was used as a material in this study. The temperature of the water where diseased fish found was 20-21°C.

### Bacteriological Examination

For microbiological analysis, samples were taken from liver, spleen and kidney from all moribund Seven khramulya. They were inoculated onto Tryptic Soy Agar (TSA) and Brain Heart Infusion Agar (BHIA). Petri plates were incubated at 24-25 °C for 24-48 h. The isolates recovered from diseased fish were identified by using conventional bacteriological method. In addition, all isolates were determined together with their biochemical characteristics using rapid identification kits such as API20E and API STAPH (Buller, 2004; Austin and Austin, 2016).

### Parasitological Examination

The presence of external parasites was investigated by examining the fresh samples from the gills and skin of diseased Seven khramulya under a light microscope. Furthermore, the samples taken from the intestine, stomach, and gallbladder of the same fish after autopsy were examined for internal parasites (Bullock, 1978; Timur and Timur, 2003).

### Histological Examination

Samples of tissues from liver, kidney, spleen, gut, gills, heart and gill immediately fixed in 10% buffered formalin and processed for paraffin embedding. Histological sections (4-5µm) were stained with haematoxylin and eosin (H&E) and examined by light microscopy (Culling, 1963).

## RESULTS

### Clinical Findings

While clinical findings such as weakness, slight loss of scales, necrosis in gills, cloud like thin white film layer on the body surface and hemorrhage in the dorsal and tail fin are remarkable in the external examination of diseased Seven khramulya (Fig. 1a,b), accumulation of fluid in the abdominal cavity, hemorrhage and hyperemia in internal organs, and splenomegaly were observed in the internal examination (Fig. 1c).

### Parasitological Findings

As a result of the parasitological examination, *Gyrodactylus* sp., one of the external monogenean parasites, was found on the gills and *Trichodina* sp., one of the protozoan ciliates, was found on the skin of the diseased Seven khramulya.

### Bacteriological Findings

Bacteria with 4 different colony morphologies reproduced in the medium at the end of the incubation



Figure 1. The loss of scales on the body surface of the diseased fish and hemorrhage on the fins (\*) (a), necrosis in the gill (b), enlargement of the spleen and hemorrhage in the abdominal cavity and hyperemia in the visceral organs (\*) (c)

period. A total of 20 bacterial isolates were obtained from these colonies, and these isolates were examined in 4 different groups based on their morphological, physiological and biochemical characteristics. The bacteria of the first isolate (n=5) were identified as *Aeromonas* sp. since they were Gram-negative, motile bacilli, gave a positive reaction to cytochrome oxidase and catalase tests and also were sensitive to O/129 test. Since isolate number 2 (n=5) was Gram-negative motility bacilli, gave a positive reaction to cytochrome and oxidase test and was sensitive to O/129 test, the isolated bacteria were identified as *Vibrio* sp. It was determined that isolates number 3 (n=5) and 4 (n=5) were Gram-positive, cluster forming, cocci shaped bacteria and also gave a negative reaction to cytochrome oxidase and a positive reaction to catalase. Therefore, these isolated bacteria were identified as *Staphylococcus* spp. According to the results of all biochemical tests, the isolated bacteria were identified as *A. hydrophila* (isolate 1), *V. fluvialis* (isolate 2), *S. warneri* (isolate 3), and *S. capitis* (isolate 4). All results obtained were confirmed by the API 20E and API STAPH kit. The morphological, physiological and biochemical characteristics of the isolated bacteria and their API profiles are presented in Table 1.

### Histopathological Findings

Histopathologically, thickening of epicardium in the heart tissue of the diseased fish (Fig. 2a), myopathy and inflammatory cell infiltration (Fig. 2b), periglomerular and tubular edema in the renal tissue of the kidney, melanomacrophage and hemosiderin foci, necrosis and inflammation reaction in the

hematopoietic tissue were detected (Fig. 2c). Furthermore, it was also remarkable that there was hyperemia in the liver tissue of infected fish, intense infiltration of inflammatory cells, and necrosis in hepatic cells (Fig. 2d). As a result of the parasitological examination, hyperplasia at the ends of the primary filaments of the gills in which *Gyrodactylus* sp. was detected (Fig. 2f), and edema in secondary lamellae were observed (Fig. 2e).

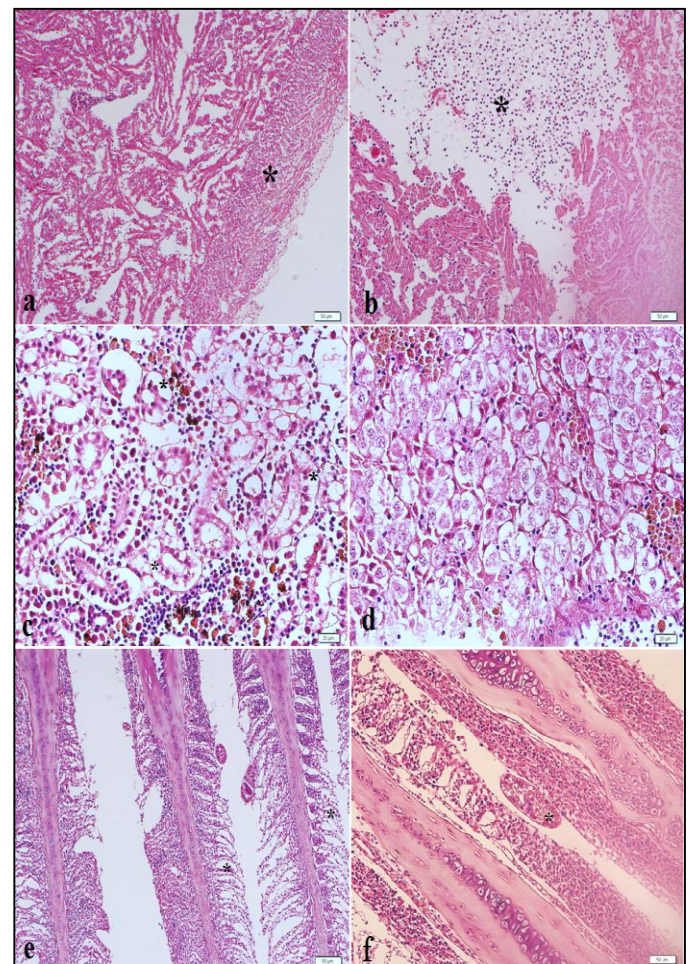


Figure 2. Thickening of epicardium (\*) (a), inflammatory cell infiltration in the heart tissue (\*) (b), periglomerular and tubular edema (\*), melano macrophage centers in the renal tissue of the kidney (c), intense infiltration of inflammatory cells and necrosis in hepatic cells (d), edema (\*) and hyperplasia in the secondary lamellae (e) and *Gyrodactylus* sp. (\*) (f)

### DISCUSSION

Stress factors, such as the increase in organic load occurring in the habitat of fish that are found in nature and cultured, oxygen deficiency and pollutants, cause bacterial diseases and therefore mortality in fish populations (Roberts, 2001; Austin and Austin, 2016).

Table 1. Morphological, physiological, and biochemical characteristics of the isolates recovered from moribund Seven khramulya and API profiles

Characteristics	Isolate <sub>1</sub> (n=5)	Isolate <sub>2</sub> (n=5)	Isolate <sub>3</sub> (n=5)	Isolate <sub>4</sub> (n=5)
Gram staining	-	-	+	+
Motility	+	+	-	-
Oxidase	+	+	-	-
Catalase	+	+	+	+
O/F	F	F	F	F
0/129- 10	-	+	-	-
0/129-150	-	+	-	-
Growth on %2 TSA	+	+	+	+
%3 TSA	-	+	+	+
%5 TSA	-	-	+	+
MCA	+	+	-	-
TCBS	+	+	-	-
Arginine dihydrolase	+	-	+	+
Lysine decarboxylase	+	-	ND	-
Ornithine decarboxylase	-	-	ND	-
H <sub>2</sub> S	-	-	ND	-
Indole	+	+	ND	-
Urease	-	-	+	+
Metil Red	+	+	ND	-
Voges Proskauer	+	-	+	+
Nitrate reduction	+	+	-	+
Urease production	-	-	+	+
Starch hydrolise	+	-	ND	-
Citrate	v	+	ND	ND
Esquline	+	+	ND	-
Arabinose	+	+	-	-
Maltoze	+	+	+	-
Mannose	+	+	+	-
Mannitole	+	+	ND	+
Trehalose	+	+	+	-
Xylose	+	+	-	-
Sorbitol	-	-	-	-
Sucrose	+	+	+	-
Inositole	-	-	-	-
Laktose	-	-	-	-
API Profile Number	3 0 4 7 1 6 7 5 7	1 0 4 4 0 2 6 5 5	7 2 1 0 1 1 3	7 1 0 2 1 0 7
Identification	<i>A. hydrophila</i>	<i>V. fluvialis</i>	<i>S. warneri</i>	<i>S. capitis</i>

+:positive reaction, -:negative reaction, V: variable, ND: not detected, O/F:Oxidative/Fermentative, MCA:Mac Conkey Agar, TCBS: Thiosulfate Citrate Bile Sucrose

In this study, the diseases causing mortality in Seven khramulya in nature was diagnosed using parasitological, bacteriological and histopathological examination methods. While bacterial agents such as *A. hydrophila*, *V. fluvialis*, *S.warneri*, and *S.capitis* were isolated and identified from the internal organs of moribund fish, some parasitary agents such as *Gyrodactylus* sp. and *Trichodina* sp. were not present in the same fish. Histopathologically, it was determined that all these agents caused serious pathological disorders especially in the internal organs of diseased fish.

Aeromonas infections are an important bacterial disease observed in many freshwater fish (Roberts, 2001; Austin and Austin, 2016). The pathogens that cause this infection include bacterial species such as *A. hydrophila*, *A. caviae*, *A. sobira*, *A. veronii*, *A. salmonicida*, and *A. bestiarum* (Timur and Timur, 2003; Buller, 2004; Austin and Austin, 2016). It was reported that mobile Aeromonas species that cause diseases in nature, aquaculture medium and even in aquarium fish production exist in large amounts in places where there is organic pollution. In the studies conducted so far, *A. hydrophila* was reported to be the

pathogen bacteria, which was defined as an opportunistic pathogen and was the most predominantly isolated pathogen among these species (Roberts, 2001; Nielsen et al., 2001; Timur and Timur, 2003). While some of the bacteria examined in this study are Gram-negative and motile bacilli and identified as *A. hydrophila* due to their morphological, physiological and biochemical characteristics, as previously reported (Buller, 2004; Austin and Austin, 2016).

It was reported that *A. hydrophila* causes primary or co-infections in cyprinid fish and causes mass deaths as a primary agent in common carps cultured in Northern Greece (Sioutas et al., 1991), and as a co-infection with *Flavobacterium* sp. in common carps in the habitat in the St. Lawrence River in Canada (Monette et al., 2006). As reported by Bohai et al. (1993) in various carp species, *A. hydrophila* and *V. fluvialis* were isolated and identified in this study. As stated previously by Monette et al (2006), we think that the reason for observing this pathogen, which was also reported in common carps in nature, in the co-infection in diseased fish examined is the physical and environmental factors.

Vibriosis disease caused by different *Vibrio* species was reported in many naturally grown or cultured freshwater and sea fish species (Roberts, 2001; Austin and Austin, 2016). *Vibrio* species causing disease in freshwater fish mostly involve pathogens such as *V. anguillarum*, *V. fluvialis* (Han-Chang, 2009). In this study, *V. fluvialis* was isolated and identified from diseased Seven khramulya, as it was reported in various diseased common carp by Bohai et al (1993).

In freshwater fish, Gram-positive bacteria such as *S. aureus*, *S. epidermidis*, *S. cohnii* subsp. *cohnii*, and *S. warneri* (Varvarigos, 2001; Akaylı et al., 2011; Austin and Austin, 2016) mainly cause staphylococcosis. There was a report indicating that *S. warneri* isolated from diseased Seven khramulya causes disease in *Oncorhynchus mykiss* cultured in our country (Metin et al., 2014). There are no studies indicating that isolated *S. capititis* causes disease in fish we found.

Protozoan parasites that cause disease in fish are defined as opportunistic or compulsory pathogens. Protozoan parasites found on fish skins include species such as *Ichthyobodo necator*, *Ichthyophthirius multifiliis*, *Trichodina* spp. (Roberts, 2001; Durborow, 2003). Although *Trichodina* sp. is a parasite that is usually and intensely found in freshwater, it is a type of parasite that causes disease in addition to primary pathogens during stress. In this study, *Trichodina* sp. was found in the skin of diseased Seven khramulya, as it was also reported by previous researchers (Sanmartin et al., 1991; Nilsen, 1995; Asmat, 2001).

Gram-negative and Gram-positive pathogen bacteria causing hemorrhagic septicemia in fish cause serious

disorders in the structure, function, and morphology of the tissues (Roberts, 2001). Histologically, it was determined in this study that bacterial agents cause co-infection and degeneration in the hepatocytes of the liver, tubular and glomerular destruction in the renal tissue, as it was stated by Yu et al (2010). As reported by Dar et al (2016), hypertrophy in the lamellae and degenerative changes in the gill epithelium in the gill tissue of silver carp (*Hypophthalmichthys molitrix*) infected with *A. sobria* were also detected in diseased Seven khramulya.

As a result, the disease observed in Seven khramulya in nature was mostly accompanied by *A. hydrophila* along with the pathogens such as *V. fluvialis*, *S. warneri*, and *S. capititis*. *S. capititis* was isolated and identified as a disease agent from diseased Seven khramulya for the first time in this study. Furthermore, we report for the first time in this comprehensive study that these pathogenic bacteria isolated and identified from co-infection may cause disease in Seven khramulya. We think that the external parasites observed in diseased fish examined act as secondary factors causing disease with bacterial pathogens.

## CONCLUSION

Common carps are among the most important freshwater fish cultured in the world and Turkey. Seven khramulya is an important fish species that is found in natural water in our country and aimed to be raised. The data in this study shed light on future intense cultivation of Seven khramulya in Turkey, as contributes to pre-identification of bacterial and parasitic diseases that may pose a risk to fish.

## REFERENCES

- Adanır D, Turutoglu H 2007. Isolation and Antibiotic Susceptibility of *Aeromonas hydrophila* in a Carp. Bulletin of the Veterinary institute in Pulawy, 51: 361-364.
- Akaylı T, Ürkü Ç, Başaran B 2011. Kültür Balıklarında *Staphylococcus cohnii* subsp. *cohnii* Enfeksiyonu. Aquatic Sciences and Engineering, 26(2): 1-12.
- Asmat GS 2001. *Trichodina porocephalusi* sp. (Ciliophora: Trichodinidae) from an Indian flatheads leeper, *Ophiocara porocephalus* (Valenciennes) (Eleotrididae). Acta Protozoologica, 40(4): 297-302.
- Austin B, Austin DA 2016. Diseases of Farmed and Wild Fish, Springer, Dordrecht, 119-131.
- Blanc MP, Banarescu J, Gaudet L, Hureu JC 1971. European Inland Water Fish. A Multilingual Catalogue. FAO, Fishing News Ltd, London, England, 187.
- Bohai X, Zhan Y, Yushen W, Taozhen C 1993. Studies on the Taxonomy of Pathogenic Bacteria of the

- Bacterial Hemorrhagic Septicemia in Cultured Fishes in Freshwater. *Acta Hydrobiologica Sinica*, 3 (English Abstract).
- Buller NB 2004. Bacteria from Fish and Other Aquatic Animals: A Practical Identification Manual. CABI Publishing, UK, 75-124.
- Bullock AM 1978, Laboratory Methods in Fish Pathology. Bailliere Tindall, London, 235-267.
- Culling CFA 1963, Handbook of Histopathological Techniques (Including Museum Technique). Second Education, Butterworth and Co. Publisher Ltd, London, 25-97.
- Dar GH, Dar SA, Kâmilî AN, Chishti MZ, Ahmad F 2016. Detection and Characterization of Potentially Pathogenic *Aeromonas sobria* Isolated from Fish *Hypophthalmichthys molitrix* (Cypriniformes: Cyprinidae). *Microbial Pathogenesis*, 91: 136-140.
- Demir O 2017. Endemik İçsu Balıkları Yetiştiriciliğinin Önemi: Eğirdir Sirazı (*Capoeta pestai* Pietschmann, 1933). Süleyman Demirel Üniversitesi Eğirdir Su Ürünleri Fakültesi Dergisi, 13(1): 88-98.
- Demirsoy A 1997. Yaşamın Temel Kuralları (Omurgalılar/Anamniyota). Hacettepe University Publications. Vol. 3, Ankara, 684.
- Durborow R.M., 2003. Protozoan Parasites. SRAC Publication, no. 4701.
- Geldiay R, Balık S 1996. Freshwater Fishes of Turkey. Ege University Publications, No: 97, Izmir, Turkey, 520.
- Guz L, Kozinska A 2004. Antibiotic Susceptibility of *Aeromonas hydrophila* and *A. sobria* isolated from Farmed Carp (*Cyprinus carpio* L.). *Bulletin of the Veterinary Institute in Pulawy*, 48: 391-395.
- Gündüz F, Çoban MZ, Yüksel F, Demirel F, Alpaslan K, Ahmet A 2018. Uzun Çayır Baraj Gölü'ndeki *Capoeta trutta* (Heckel, 1843)'nın Üreme Biyolojisi. Kahramanmaraş Sütçü İmam Üniversitesi Tarım ve Doğa Dergisi, 21(1): 51-57.
- Han-Chang S 2009. Isolation and Identification of a Pathogenic *Vibrio* sp. from silver carp (*Hypophthalmichthys molitrix*). *Freshwater Fisheries*, 4.
- Howes GJ 1991. Cyprinid Fishes: Systematics, Biology and Explanation (Systematics and Biogeography: An overview, Chapman & Hall, London: Ed. Winfield IJ, Nelson JS), 1-33.
- Keskin N, Erk'akan F 1987. Ülkemiz Tatlı Su Balıklarında Ligulosis. Hacettepe Fen ve Mühendislik Bilimleri Dergisi, 8: 57-70.
- Koyun M, Atıcı AA 2018. First Record of *Lernaea cyprinacea* (Crustacea: Copepoda) on *Capoeta capoeta* (Actinopterygii: Cyprinidae) from Karasu Creek (Van) Eastern Anatolia. *Biharean Biologist*, 12 (2): 70-72.
- Malek M, Mobedi I 2001. Occurrence of *Clinostomum complanatum* (Rudolphi, 1819) (Digenea: Clinostomatidae) in *Capoeta capoeta gracilis* (Osteichthys: Cyprinidae) from Shiroud River, Iran. *Iranian Journal of Public Health*, 30(3-4): 95-98.
- Metin S, Kubilay A, Onuk EE, Didinen BI, Yildirim P 2014. First Isolation of *Staphylococcus warneri* from Cultured Rainbow trout (*Oncorhynchus mykiss*) Broodstock in Turkey. *Bulletin of the European Association of Fish Pathologists*, 34: 165-174.
- Monette S, Dallaire AD, Mingelbier M, Groman D, Uhland C, Richard JP, Leighton FA 2006. Massive Mortality of Common Carp (*Cyprinus carpio*) in the St. Lawrence River in 2001: Diagnostic Investigation and Experimental Induction of Lymphocytic cephalitis. *Veterinary Pathology*, 43(3): 302-310.
- Nielsen ME, Høi L, Schmidt AS, Qian D, Shimada T, Shen JY, Larsen JL 2001. Is *Aeromonas hydrophila* the Dominant Motile *Aeromonas* species that Causes Disease Outbreaks in Aquaculture Production in the Zhejiang Province of China?. *Diseases of Aquatic Organisms*, 46(1): 23-29.
- Nilsen F 1995. Description of *Trichodina hippoglossi* sp. from Farmed Atlantic Halibut Larvae *Hippoglossus hippoglossus*. *Diseases of Aquatic Organisms*, 21(3): 209-214.
- Pullin RSV 1986. The world Wide Status of Carp Culture. *Aquaculture of Cyprinids*. INRA, Paris, France, 21-34.
- Raissy M, Ansari M 2012. Parasites of Some Fresh Water Fish from Arman Driver, Chaharmahal Va Bakhtyari Province, Iran. *Iranian Journal of Parasitology*, 7(1): 73-76.
- Raissy M, Ansari M, Moumeni M, Goudarzi MA, Sohrabi HR, Rashedi M 2010. An Epizootic of Ichthyophthiriasis Among Fishes in Armand River, Iran. *Journal of Cell and Animal Biology*, 4(10): 150-153.
- Roberts RJ 2001. The Bacteriology of Teleosts. (Fish Pathology, A John Wiley & Sons, Ltd., Publication, Philadelphia: Ed. Roberts RJ) 315-321.
- Sanmartin ML, Fernandez J, Tojo JL, Santamarina MT, Estevez J, Ubeira F 1991. *Trichodina* sp.: Effects on the Growth of Farmed turbot (*Scophthalmus maximus*). *Bulletin of the European Association of Fish Pathologists*, 11: 89-91.
- Sioutas S, Hoffmann RW, Pfeil-Putzien C, Fischer-Scherl T 1991. Carp Erythrodermatitis (CE) due to an *Aeromonas hydrophila* Infection. *Journal of Veterinary Medicine*, 38(10): 186-194.
- Şen B, Canpolat Ö 2011. Elazığ İlinin Bazı İlçelerinde Balık Eti Tüketimi. *Ecological Life Sciences*, 6(2): 43-52.
- Timur G, Timur M 2003. Balık Hastalıkları, İstanbul Üniversitesi Su Ürünleri Fakültesi Yayınları, Yayın no:4426, İstanbul, 350-421.
- TUIK, 2016. Türkiye İstatistik Kurumu, Haber bülteni. Su Ürünleri, Sayı 21720.

- Varvarigos, P. 2001. Gram Positive Coccobacteria (Micrococcaceae, Streptococcaceae) causing systemic disease in intensively farmed fish, [http://www.vetcare.gr/ARTPRES/Gram\\_positive\\_cocci.htm](http://www.vetcare.gr/ARTPRES/Gram_positive_cocci.htm). (date accessed:12.02.2019).
- Yazıcıoğlu O, Yılmaz M 2011. Hirfanlı Baraj Gölü'nde Yaşayan Siraz Balığı [*Capoeta sieboldii* (Steindachner, 1864)]'nın Beslenme Rejimi. Karadeniz Fen Bilimleri Dergisi, 2(1): 62-73.
- Yılmaz H, Aras NM, Haliloğlu Hİ, Yılmaz M 2003. An Investigation on the Surumi Production from Siraz "*Capoeta capoeta umbla*" fish species. Atatürk Üniversitesi Ziraat Fakültesi Dergisi, 34(1): 63-67.
- Yu JH, Han JJ, Kim HJ, Kang SG, Park SW 2010. First Report of *Aeromonas veronii* Infection in Farmed Israeli Carp *Cyprinus carpio* in Korea. Journal of Fish Pathology, 23(2): 165-176.